

Mercury-Specific Lymphocytes: An Indication of Mercury Allergy in Man

VERA D. M. STEJSKAL,^{1,3} MARGIT FORSBECK,² KARIN E. CEDERBRANT,¹ and OLA ASTEMAN¹

Accepted: July 28, 1995

In this study, 18 patients with oral lichen planus (OLP), adjacent to amalgam fillings, were tested *in vitro* with an optimized lymphocyte proliferation test, MELISA (memory lymphocyte immunostimulation assay) and with a patch test. Twenty subjects with amalgam fillings but without oral discomfort and 12 amalgam-free subjects served as controls. The results show that patients with OLP have significantly higher lymphocyte reactivity to inorganic mercury, a corrosion product of amalgam, compared to control groups. Removal of amalgam fillings resulted in the disappearance of oral mucosal changes, thus indicating a causal relationship. Positive responses to phenylmercury (phenyl-Hg), a bactericidal agent in rootfillings and in pharmaceutical preparations, were also noted in the oral lichen group but not in the control groups. Thus, low-grade chronic exposure to mercury may induce a state of systemic sensitization as verified by Hg-specific lymphocyte reactivity *in vitro*.

KEY WORDS: Cell-mediated immunity; silver amalgam; mercury; human memory lymphocytes; MELISA.

INTRODUCTION

For many years there has been an ongoing debate concerning the harmful effects of dental amalgam on man (1, 2). Silver amalgam is an alloy consisting of 50% metallic mercury and other metals such as silver, tin, zinc, and copper. It has generally been accepted that inadvertent exposure to mercury results in metal deposition in the body and systemic mercury poisoning both in experimental animals and in man (3, 4). Hence, it seems paradoxical that the impact of dental amalgam on the general well-being of mankind is so controversial. Low concentrations of mercury, released from dental amalgam, may not be sufficient to induce general toxic effects

in all exposed subjects but may, nevertheless, affect some, genetically sensitive individuals (4, 5). In addition to mercury released from dental amalgam, other sources of mercury exposure are organic mercurials such as phenyl-Hg and ethylmercury salts frequently used as bactericidal agents in pharmaceutical products.

The sensitizing properties of mercurials are difficult to evaluate by standard skin tests due to irritative (toxic) effects of mercury compounds on the skin. We have previously demonstrated that immune responses induced by drugs and other low molecular chemicals such as formaldehyde and Kathon CG can be verified *in vitro* by the presence of antigen-specific memory cells (6–8). In this study we asked if there exists a state of systemic sensitization to mercury in patients suffering from oral mucosal changes (oral lichen planus; OLP) located near amalgam fillings (9–11). The immune response to mercury was studied by an optimized lymphocyte proliferation test, MELISA (12), and by patch test. Amalgam-free subjects and subjects without obvious oral discomfort due to amalgam, served as controls. The results show a significantly increased lymphocyte reactivity to mercury in patients with OLP.

MATERIALS AND METHODS

Patients and Controls

Eighteen patients (14 females aged 29–64 years, mean = 55.4 years; and 4 males aged 37–55 years; mean = 42.8 years) with OLP as verified by PAD (pathologic anatomical diagnosis) biopsies adjacent to amalgam fillings were enrolled in the study. The patients were referred to the Dermatology Clinics for oral discomfort such as burning or itching. Medical history revealed that some of them also suffered from systemic symptoms such as arthralgia, myalgia, eczema, and chronic malaise. Two patients (S50 and S75) suffered from diabetes.

¹Astra AB, Safety Assessment, S-151 85 Södertälje, Sweden.

²Sophiahemmet, Stockholm, Sweden.

³To whom correspondence should be addressed. Fax: +46 8 553 289 27.

Twenty persons with amalgam fillings (females aged 24–64 years; mean = 47.6 years) but without oral lichenoid changes were recruited as controls for *in vitro* lymphocyte studies. Ten of them had also been exposed to amalgam at work, as dental assistants. Twelve controls without amalgam fillings (6 females aged 14–28 years, mean = 17.8 years; and 6 males aged 15–19 years; mean = 17.3 years) were also tested. One of them (TL43) worked as a dental assistant. No age-matched amalgam-free subjects were available for the study. In Sweden, virtually all subjects over the age of 25 have been exposed to amalgam due to its generous use in restorative dentistry.

MELISA

MELISA (memory lymphocyte immunostimulation assay), based on a protocol originally used in our laboratory (6), was optimized for the study of lymphocyte reactivity to various mercurial compounds (12). Venous blood was collected in sterile vacutainer tubes with polystyrene beads (Becton Dickinson, England) and defibrinated by shaking. Lymphocytes were isolated on Ficoll-Paque (Pharmacia, Sweden). After separation the cells were washed once with RPMI 1640 (Gibco, Scotland) containing 10 mM HEPES, 8 mg/L gentamycin, and 4 mM L-glutamine. The cells were then incubated at 37°C for 30 min in a cell culture flask to reduce the amount of monocytes by plastic adherence. Nonadherent cells were recovered and diluted to 1×10^6 cells/ml in complete RPMI 1640 with 10% inactivated human AB+ serum. The cells were cultivated in macrocultures, containing 1×10^6 lymphocytes, in 48-well plates (Costar, The Netherlands) to which antigens had been added in two- or threefold dilutions within a given range: HgCl₂, 0.03–4 µg/ml; and phenylmercuric acetate, 0.008–1 µg/ml. HgCl₂ (4 µg/ml) and phenyl-Hg (0.5 µg/ml) resulted in some patients in suboptimal proliferative responses. Concentrations higher than 9 µg/ml of HgCl₂ and 1 µg/ml phenyl-Hg were uniformly toxic to lymphocytes. At least three consecutive concentrations were used for each metal salt. Three or six control cultures, without antigens, provided information about the spontaneous proliferation of lymphocytes. PPD (purified protein derivative; tuberculin) was used as a positive control antigen since BCG (Bacille Calmette Guerin) vaccination has been obligatory in the Swedish population. Following 5 days of incubation, fresh 48-well plates were supplemented with 3 µCi methyl-³H-thymidine (Amersham, England; spec. act., ~3.2 TBq/mmol) per well and 600 µl of cell suspension from each cell culture were added. As found in preliminary experiments, this

procedure resulted in improved specificity of lymphoblast labeling due to retention of macrophages in culture plates. After incubation at 37°C for another 4 hr. the cells were harvested in an automatic cell harvester (Inotech, Switzerland) and the radioactivity was measured in a liquid scintillation counter (LKB/Wallac, Finland). The increase in ³H-thymidine incorporation in antigen-treated cultures was expressed as a stimulation index (SI), which is defined as

$$SI = \frac{\text{cpm in antigen-treated cultures}}{\text{mean cpm in untreated cultures}}$$

The maximal stimulation index indicates the maximal proliferation obtained at the optimal concentration of given metal salt.

Lymphocyte proliferation was also expressed as Δcpm, which is defined as follows:

$$\Delta\text{cpm} = \text{cpm in antigen-treated cultures} \\ - \text{mean cpm in untreated cultures}$$

Cells from the 5-day cultures were also screened for the presence of lymphoblasts using May-Grünwald-Giemsa-stained cytospin preparations. Morphological evaluation provides valuable information about several factors important for the outcome of MELISA such as cell viability or the presence of activated macrophages. Further, the presence of lymphoblasts in cultures verifies positive results based on DNA synthesis. An SI ≥ 3 was regarded as positive. SI values between 2 and 3 were regarded as weakly positive. SI values less than 2 were regarded as negative. The results were considered positive only if increased ³H-thymidine incorporation correlated with an increased number of lymphoblasts.

Statistical Evaluation

Lymphocyte responses induced by mercurials were analyzed by three approaches. The first approach was to classify subjects in the patient and control groups into positive and negative responders based on their SI. As mentioned previously, a subject was classified as a positive responder to a given metal if the SI was equal to or greater than 3. Pairwise comparisons between the different groups based on the contingency tables resulting from this classification were performed using Fischer's exact test. The second approach was to analyze SI values without any classification into positive and negative responders. The differences between the groups were evaluated using Wilcoxon's rank sum test. The *P* values from this test were based on the normal approximation

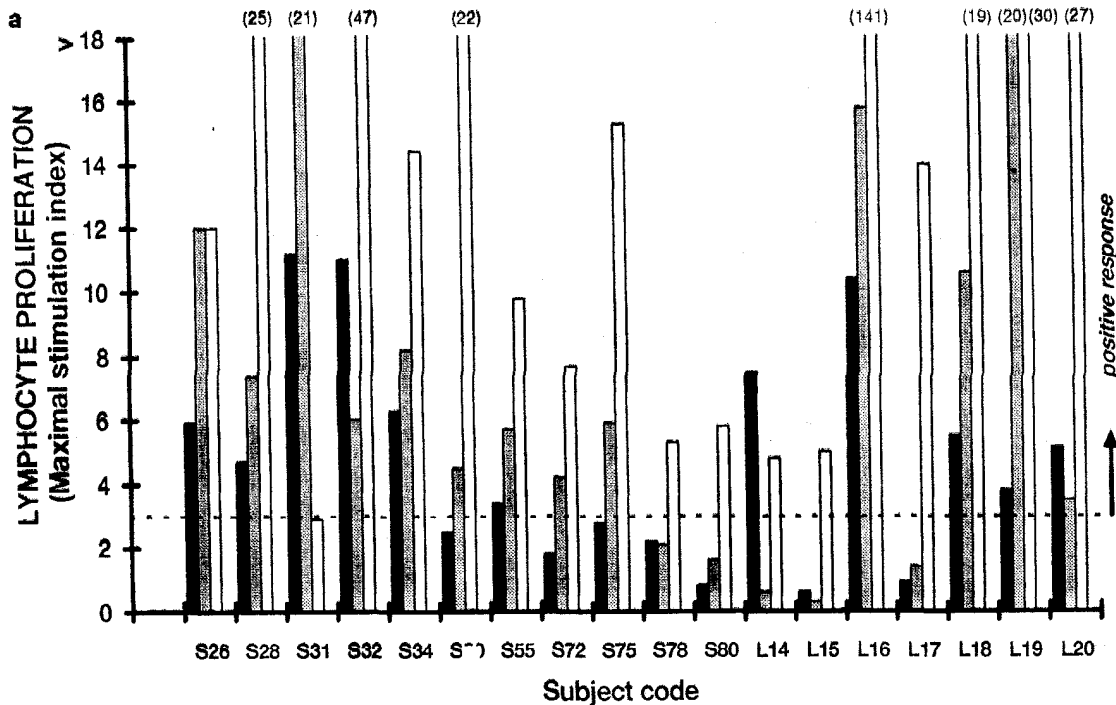


Fig. 1a. Lymphocyte proliferation to high concentrations of HgCl_2 ($>0.5 \mu\text{g/ml}$) (white bars), to low concentrations of HgCl_2 ($\leq 0.5 \mu\text{g/ml}$) (gray bars), and to phenyl-Hg (black bars) in patients with OLP. Numbers in parentheses show stimulation indexes exceeding the scale. Maximal stimulation indexes are shown.

with a continuity correction of 0.5. Third, the same method was also used for analysis of Δcpm .

Comparisons among the groups with respect to the background proliferation (untreated lymphocyte cultures) and positive control PPD-induced proliferation were also performed and evaluated using Wilcoxon's rank sum test. All statistical tests were two-sided at the 5% significance level and were performed using SAS statistical software. *P* values were rounded to three decimal places; statistical significance was declared when the *P* value was less than 0.05.

Patch Tests

Patients with OLP were patch tested as described previously (13) with a dental screening series (Chemotechnique Diagnostics AB, Sweden) which included phenyl-Hg acetate, 0.01% in aqua and metallic Hg^0 , 0.5% in petrolatum. The patch tests were performed with Finn chambers (Epitest Helsinki, Finland) on Scanpor. The tests were applied for 48 hr on the patient's back and read after 72 hr. Persistent erythema, papules, or vesicles on the skin were considered as a positive reaction.

RESULTS

Results of MELISA in the 18 OLP patients are shown in Fig. 1a. Lymphocytes from all but one patient (S31) were stimulated by high concentrations of HgCl_2 ($>0.5 \mu\text{g/ml}$). Thirteen patients (72%) also responded to low concentrations of HgCl_2 ($\leq 0.5 \mu\text{g/ml}$). Lymphocytes from 11 patients (61%) responded to phenyl-Hg. Lymphocytes from dental assistants with amalgam fillings (L1–L13) showed responses similar to those of control subjects exposed to amalgam through dental fillings only (Fig. 1b). Thus, 6 of 10 dental assistants (60%) and 7 of 10 amalgam bearers (70%) responded to high concentrations of HgCl_2 . In contrast, only 2 of the 20 amalgam-exposed control subjects responded to low doses of HgCl_2 , while only 1 responded to phenyl-Hg. In amalgam-free controls, 7 of 12 (58%) had positive responses to high doses of HgCl_2 (Fig. 1c). Low doses of HgCl_2 or phenyl-Hg did not induce lymphocyte proliferation in any of these subjects. Lymphocytes from four assistants, two amalgam bearers, and five amalgam-free controls did not respond to any of the HgCl_2 concentrations tested.

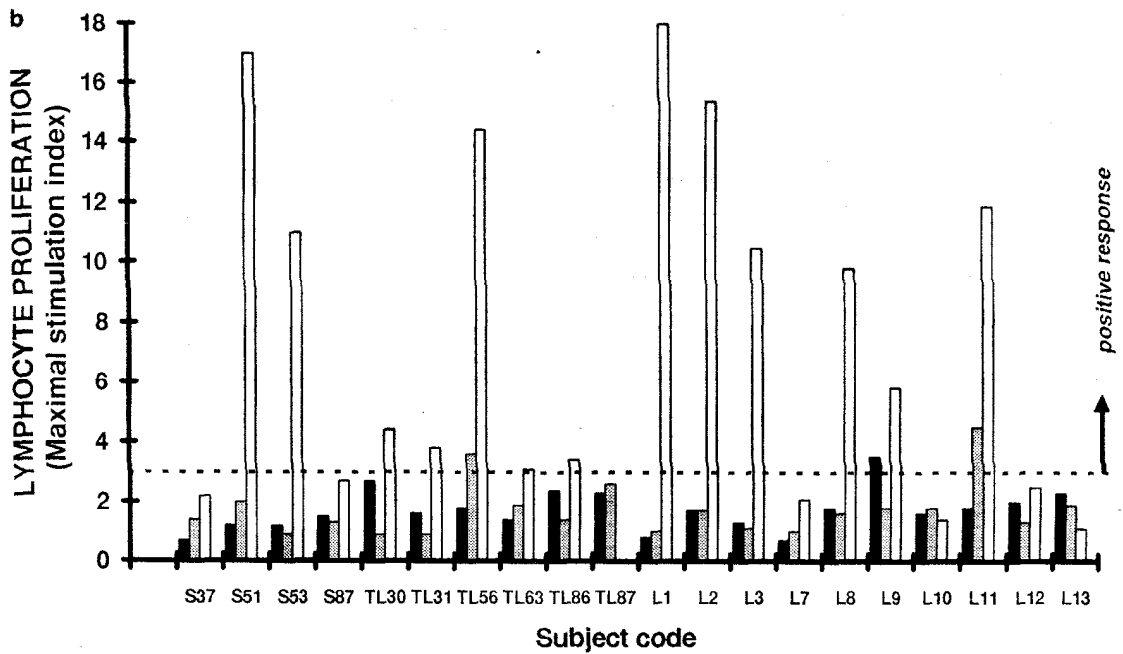


Fig. 1b. Lymphocyte proliferation to high concentrations of HgCl₂ (>0.5 µg/ml) (white bars), to low concentrations of HgCl₂ (≤0.5 µg/ml) (gray bars), and to phenyl-Hg (black bars) in controls with amalgam (S37–TL87) and in dental assistants (L1–L13). Maximal stimulation indexes are shown.

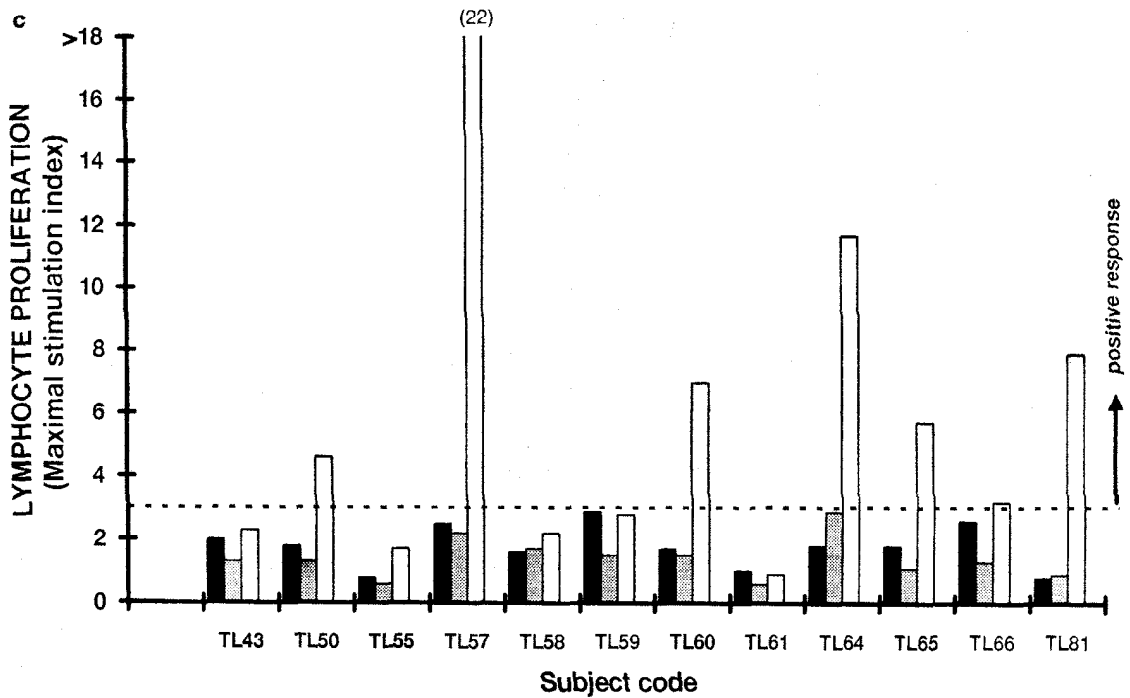


Fig. 1c. Lymphocyte proliferation to high concentrations of HgCl₂ (>0.5 µg/ml) (white bars), to low concentrations of HgCl₂ (≤0.5 µg/ml) (gray bars), and to phenyl-Hg (black bars) in amalgam-free controls. Maximal stimulation indexes are shown.

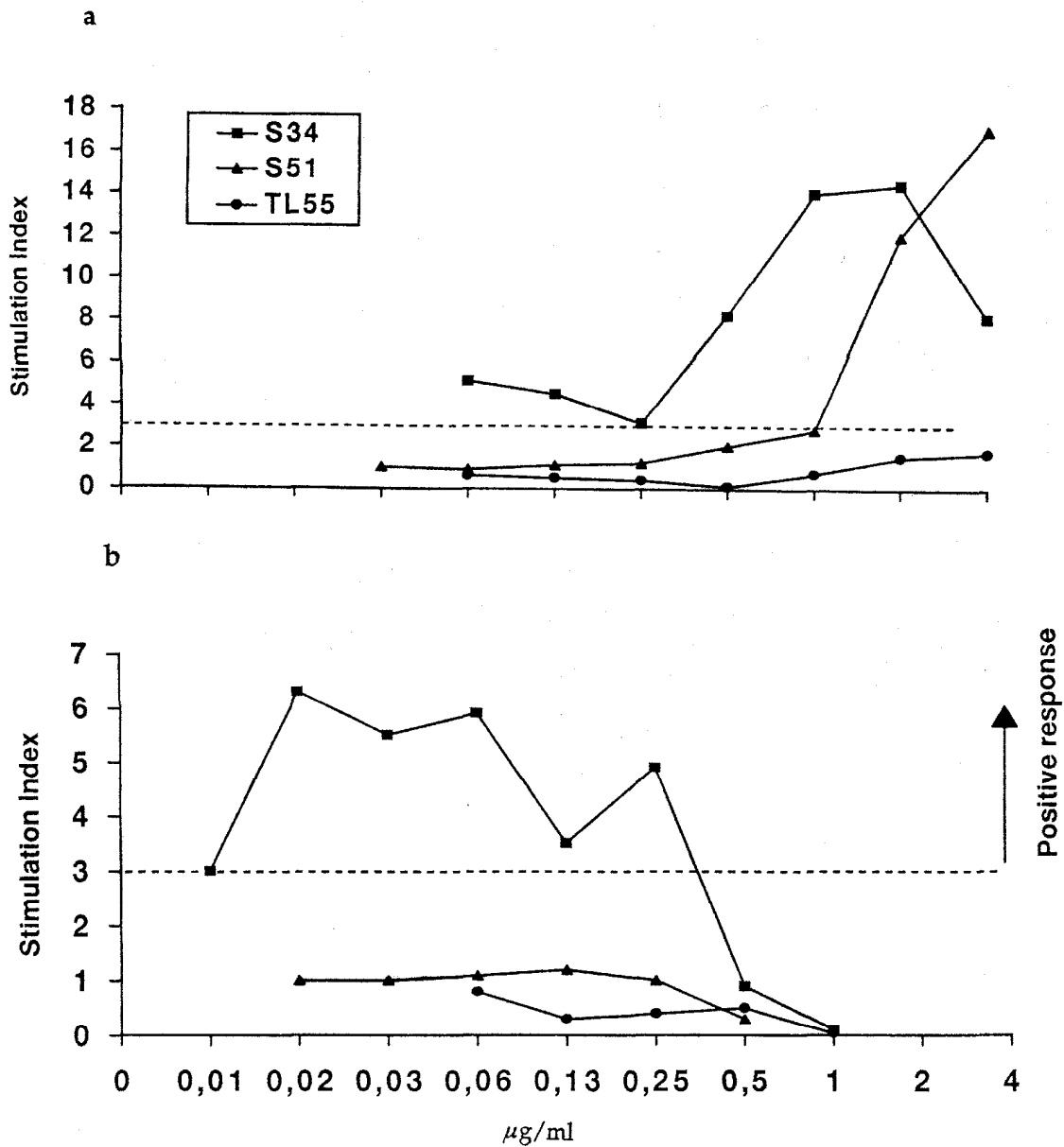


Fig. 2. Lymphocyte proliferation in the presence of various concentrations of HgCl₂ (a) and phenyl-Hg (b) in an OLP patient (S34; ■), in a control subject with amalgam (S51; ▲), and in an amalgam-free subject (TL55; ●).

Mercury compounds stimulated lymphocytes in a dose-dependent manner (Figs. 2a and b). Lymphocytes from an OLP patient (S34) responded to a wide range of concentrations of HgCl₂ (Fig. 2a) and to phenyl-Hg (Fig. 2b). In contrast, lymphocytes from a control subject with amalgam (S51) responded only to high doses of HgCl₂ (1–4 μg/ml) and were negative to phenyl-Hg. An example of negative results with both high and low doses of HgCl₂ and phenyl-Hg in an amalgam-free control (TL55) is also shown.

Results from a pairwise Fischer's exact test using classification of controls and patients into responders and nonresponders according to an SI ≥ 3 are shown in Table I. Regarding lymphocyte responses to high (>0.5 μg/ml) concentrations of HgCl₂, the pairwise comparisons between OLP patients and three control groups showed statistically increased Hg-induced proliferation in the former group, except for group of controls with amalgams. When the results from all control groups were pooled and compared to those from OLP patients, the

Table I. Pairwise Comparisons of Proliferative Responses to Mercurials Based on a SI ≥ 3 Among OLP Patients and Control Groups

Antigen in culture	OLP patients vs			
	Dental assistants	Controls with amalgam	Amalgam-free controls	All controls
HgCl ₂				
>0.5 $\mu\text{g/ml}$	0.041 ^a	0.250	0.026	0.036
$\leq 0.5 \mu\text{g/ml}$	0.004	0.004	<0.001	<0.001
Phenyl-Hg	0.016	0.002	0.001	<0.001

^aP values from the two-sided Fischer's exact test.

difference was also significant ($P = 0.036$). Regarding low doses of HgCl₂ ($\leq 0.5 \mu\text{g/ml}$), the results showed that all pairwise comparisons were significant. This held true when the results from all control groups were combined and compared to those from the OLP patients ($P < 0.001$). The results from the analysis of lymphocyte reactivity to phenyl-Hg were similar to that to low doses of HgCl₂. When data from all controls were combined

Table II. Pairwise Comparisons of Control and PPD Responses in OLP Patients and in Control Groups

Lymphocyte cultures	OLP patients vs			
	Dental assistants	Controls with amalgam	Amalgam-free controls	All controls
Control	0.042 ^a	0.905	0.816	0.298
PPD	0.058	0.350	0.006	0.368

^aP values from the two-sided Wilcoxon's rank sum test.

Table III. PPD-Induced and Spontaneous Proliferation in OLP Patients and Control Groups

Code	Oral lichen patients		Controls with amalgam			Amalgam-free controls		
	Control	PPD	Code	Control	PPD	Code	Control	PPD
S26	1,469 (1,178) ^a	336,652	S37	4,922 (895)	210,377	TL43 ^b	1,286 (186)	49,919
S28	1,345 (306)	409,009	S51	407 (86)	102,877	TL50	614 (161)	6,324
S31	1,327 (655)	142,468	S53	4,463 (1,381)	492,472	TL55	5,058 (3,892)	149,144
S32	532 (129)	188,356	S87	2,497 (475)	127,381	TL57	455 (184)	16,284
S34	1,096 (188)	81,461	TL30	1,958 (477)	148,188	TL58	3,566 (1,512)	138,484
S50	632 (64)	139,004	TL31	615 (151)	911,857	TL59	3,857 (1,126)	125,597
S55	1,598 (798)	6,663	TL56	1,553 (270)	120,023	TL60	2,804 (1,447)	205,777
S72	1,860 (374)	109,870	TL63	657 (224)	98,659	TL61	5,933 (2,565)	89,740
S75	2,128 (857)	522,042	TL86	752 (186)	23,629	TL64	1,285 (477)	60,399
S78	1,218 (115)	108,500	TL87	1,630 (1,561)	375,851	TL65	555 (175)	65,441
S80	1,376 (308)	84,531	L1 ^b	4,559 (1,681)	239,432	TL66	1,561 (671)	66,505
L14	1,193 (581)	656,600	L2 ^b	4,103 (521)	746,349	TL81	840 (163)	27,205
L15	13,133 (6,066)	201,963	L3 ^b	659 (134)	407,150			
L16	1,080 (349)	945,483	L7 ^b	2,095 (830)	364,211			
L17	2,472 (398)	795,114	L8 ^b	4,182 (1,624)	510,514			
L18	1,551 (398)	701,865	L9 ^b	1,114 (152)	882,092			
L19	2,876 (2,239)	620,579	L10 ^b	2,333 (478)	414,643			
L20	1,098 (201)	61,967	L11 ^b	4,022 (35)	647,029			
			L12 ^b	2,624 (256)	520,587			
			L13 ^b	1,641 (176)	673,148			

^aMean cpm. Standard deviation is shown in parentheses.

^bOccupationally Hg-exposed dental assistants.

and compared to those from OLP patients, the increased proliferative responses by OLP-patients were also highly significant ($P < 0.001$).

The comparison of proliferative responses among the groups based on Δcpm or on total SIs largely confirmed results based on SI ≥ 3 values (data not shown).

Statistical evaluation of possible differences in cpm among control and PPD cultures are shown in Table II. ³H-Thymidine incorporation in control cultures did not differ among the groups except for dental assistants, whose control proliferation was higher than the proliferation of OLP patients ($P = 0.042$). Lymphocyte proliferative responses induced by PPD were similar among the groups except for amalgam-free controls, whose lymphocytes reacted less vigorously to PPD ($P = 0.006$). The raw cpm values used for statistical evaluation are shown in Table III.

The results of patch tests are summarized in Table IV. Eleven of 18 OLP patients were positive to metallic Hg⁰ (61%) and 8 of 17 patients tested with phenyl-Hg were positive (47%). Seven of 17 patients reacted to both mercurials (41%).

As the results of skin tests and of lymphocyte proliferative tests suggested the presence of cell-mediated hypersensitivity to mercury compounds, the patients were advised to remove their amalgam fillings. Amalgam was replaced with gold, ceramics, or composite material. The period of amalgam removal varied from a few months to several years. A questionnaire was sent to all

Table IV. Results from Patch Tests^a

Patient code	Test compound	
	Hg ⁰	Phenyl-Hg
S26	+	-
S28	-	+
S31	+	+
S32	+	+
S34	-	-
S50	+	-
S55	-	-
S72	-	-
S75	-	-
S78	+	+
S80	-	-
L14	+	ND
L15	+	+
L16	+	+
L17	+	+
L18	-	-
L19	+	+
L20	+	±

^aPatch tests were graded as follows: -, negative response; ±, weakly positive (redness); +, positive (papulae).

patients regarding subjective symptoms experienced following amalgam removal. Seven of 16 patients (43%) who underwent removal of amalgam experienced temporary worsening of local oral symptoms. In some patients systemic symptoms such as generalized malaise, tremor, arthralgia, and fibromyalgia became aggravated. However, both local and systemic symptoms gradually diminished following amalgam replacement, until they finally disappeared.

DISCUSSION

The presence of mercury-specific lymphocytes in patients with OLP adjacent to amalgam fillings indicates that mercury, similar to nickel, beryllium, and gold, can induce cell-mediated hypersensitivity in susceptible individuals (14-16). Recently, the detection of Hg-specific T cells in sensitized mice was reported by Gleichmann's group (17). The data presented in this study support an immunologic etiology of oral lichen as suggested previously by other groups (18-20). The high prevalence of Hg-positive patch tests in OLP patients is in agreement with reports of others (21, 22). Two patients showed positive patch tests but were negative in MELISA. In these cases MELISA was performed 4 years following amalgam removal and patch testing. The diminished lymphocyte reactivity to mercury following amalgam removal could be due to mercury-specific desensitization as demonstrated for other antigens in experimental animals (23, 24).

Positive proliferative responses to mercurials in the OLP group cannot be explained by an unspecific increase in lymphocyte activity since proliferation in antigen-free control cultures was similar in all groups. Further, lymphocyte proliferation induced by an unrelated antigen PPD was also similar, except for responses of amalgam-free subjects. The decreased response of amalgam-free controls to PPD was expected since the mean age of this group was lower and the vaccination against BCG was discontinued in Sweden in 1975.

As described previously (25), the majority of lymphocytes detected in inflamed mucosa adjacent to amalgam fillings is T cells. The presence of metal-containing macrophages has also been observed. Thus, phagocytic cells may actively transport metals via the blood and lymphatic system throughout the entire body (26, 27). Inflammatory changes have been observed in some but not all patients suffering from oral amalgam tattoos, which may reflect individual sensitivity (28). Cell-mediated mercury hypersensitivity such as exanthema has been noted previously and was induced by dental treatment (29) or after topical application of inorganic mercury (30).

With regard to other mercurials, reactivity to phenyl-Hg was also detected in patients with OLP. Phenyl-Hg salts are used as preservatives in eyedrops and cosmetics and may induce allergic reactions (31). In the oral cavity, phenyl-Hg has been identified as one of the several toxic components of N₂, a previously widely used root filling material (32). The majority of patients enrolled in this study had old root fillings which may have contained N₂.

Another organic mercury compound, Thimerosal (sodium ethylmercurythiosalicylate; thiomersalate, mercuriothiolate), also called Merthiolate, Merzonin, Mertorgan, and Merfamin, is widely used as a preservative in several vaccines, soft contact lens fluids, and immunoglobulin preparations. It is well-known that ethylmercury (ethyl-Hg) derivatives are exceedingly toxic to brain tissue (33, 34). An alarmingly high prevalence of Thimerosal-positive patch tests has been reported in Scandinavia (35). Recently, ethyl-Hg has been found to be the major epitope in Thimerosal hypersensitivity (36). Six patients with OLP reacted positively to Thimerosal in MELISA and the patch test (data not shown).

Thus, the immune system of susceptible individuals may be triggered by several different mercury compounds. As shown for lymphocytes (12) and by patch testing (37, 38), inorganic mercury, phenyl-Hg, and Thimerosal behave as separate antigenic epitopes and do not cross-react.

It has generally been anticipated that inorganic mercury compounds, such as HgCl_2 , function as a mitogen for human and animal lymphocytes *in vitro* (39, 40). This type of an explanation is difficult to reconcile with the results of this study since four dental assistants, two amalgam bearers, and five amalgam-free controls did not respond to any concentration of HgCl_2 . The discrepancy may be explained by methodological differences in performing the MELISA test versus the conventional lymphocyte proliferation test (12, 41). For example, previous studies used higher concentrations of HgCl_2 for stimulation of lymphocytes *in vitro*. Under these conditions, differences between lymphocyte responses of mercury-sensitized and those of nonsensitized individuals may not be obvious.

As shown in the current study, the majority of patients responding in MELISA could be detected by patch testing. However, patch tests with mercury compounds can induce sensitization (42) or systemic side effects in susceptible individuals (Marcusson JA, unpublished observations). Therefore, patch testing with mercurials should be avoided in patients with known or suspected metal sensitivity. With regard to sensitivity, five patch test-negative OLP patients responded positively in MELISA, which may indicate a higher sensitivity of the latter (6).

Mercuric ions possess a high affinity for thiol(SH)groups. Since these chemical moieties are ubiquitous components of proteins, mercurials can disturb many physiological functions in which proteins are involved. From an immunological point of view, binding of mercury or other metals with a strong affinity for SH groups (e.g., gold, cadmium, or lead) to autologous proteins changes their antigenicity and makes them "foreign" and therefore vulnerable to the attack of immunocompetent cells. Small molecules, such as metals, have not previously been considered to be of sufficient size to induce the formation of specific antibodies. This belief has been held despite the fact that metals have long been known to induce cell-mediated immunity, such as contact hypersensitivity (14–16). The findings of metal-specific lymphocytes in the blood of metal-allergic patients indicate that in an immunological context, metals behave as independent antigenic determinants (epitopes). Recently, Wylie and co-workers reported successful induction in mice of an antibody that reacts specifically with mercuric ions in solution regardless of the presence of a protein carrier (43). Furthermore, exposure to mercury or gold can induce autoimmune diseases in genetically predisposed animals (2, 5, 44, 45). In a study published by Jontell and co-workers (46), a strong association was found between HLA-DR3 and

OLP, suggesting an autoimmune component in the pathogenesis of this disorder.

Several case reports indicate that patients with oral mucosal changes adjacent to dental fillings may also suffer from various autoimmune diseases such as lupus erythematosus, Crohn's disease, ulcerative colitis, and diabetes (47–50). Acute mercury intoxication with lichenoid eruption and antinuclear antibodies has been reported in an occupationally exposed worker (51). In a recent study from our laboratory, patients with mucosal changes adjacent to metal fillings or restorations and suffering from chronic fatigue (CFS) exhibited strong proliferative responses *in vitro* not only to mercury but also to other metals, such as gold, palladium, and nickel (12). These results were confirmed in 26 patients with CFS-like symptoms who showed signs of basal ganglia degeneration by magnetic resonance imaging. Seventy-seven healthy subjects with amalgam and other metallic restorations had a significantly lower prevalence of positive metal responses and no abnormal changes in the brain (52).

CONCLUSIONS

The results of this study show that lymphocyte reactivity to mercury salts *in vitro* may be used for an objective diagnosis of mercury allergy in man. The evidence of systemic sensitization together with the known deposition of mercury in vital organs (1–6, 53, 54) offers new possibilities for study of the role of mercury-sensitized lymphocytes in pathological processes underlying autoimmune and other inflammatory diseases.

ACKNOWLEDGMENTS

We thank Dr. Sven Langworth for access to occupationally exposed controls, Dr. Anders Åkesson for the performance of PADs, laboratory engineer Maritha Marcusson-Ståhl for performing MELISA with remarkable skill, and last but not least, Irene Olsén and Teija Lindh, who helped with the preparation of the manuscript. Astra AB, The Swedish National Board for Technical Development, The National Chemical Inspectorate, and the European Commission BIOTECH programme "In Vitro Immunotoxicology" sponsored the project.

REFERENCES

1. Goering PL, Galloway WD, Clarkson TW, Lorscheider FL, Berlin M, Rowland AS: Symposium overview, toxicity assessment of

- mercury vapor from dental amalgams. *Fund Appl Toxicol* 19:319–329, 1992
2. Eneström S, Hultman P: Does amalgam affect the immune system? A controversial issue. *Int Arch Allergy Immunol* 106:180–203, 1995
 3. Chang LW: Neurotoxic effects of mercury—A review. *Environ Res* 14:329–373, 1977
 4. Kazantzis G: The role of hypersensitivity and the immune response in influencing susceptibility to metal toxicity. *Environ Health Perspect* 25:111–118, 1978
 5. Hultman P, Johansson U, Turley SJ, Lindh U, Eneström S, Pollard KM: Adverse immunological effects and autoimmunity induced by dental amalgam and alloy in mice. *FASEB J* 8:1183–1190, 1994
 6. Stejskal VDM, Olin RG, Forsbeck M: The lymphocyte transformation test for diagnosis of drug-induced occupational allergy. *J Allergy Clin Immunol* 77:411–426, 1986
 7. Stejskal VDM: Allergy to drugs and other chemicals diagnosed by the presence of specific memory cells in human blood. *In* *Realm of Tolerance*, Ivanyi P (eds). Berlin, New York, London, Springer-Verlag 1989, pp 213–224
 8. Stejskal VDM, Forsbeck M, Nilsson R: Lymphocyte transformation test for diagnosis of isothiazolinone allergy in man. *J Invest Dermatol* 94:798–802, 1990
 9. Jolly M, Moule AJ, Freeman S: Amalgam-related chronic ulceration of oral mucosa. *Br Dent J* 160:434–437, 1986
 10. James J, Ferguson MM, Forsyth A, Tulloch N, Lamey PJ: Oral lichenoid reactions related to mercury sensitivity. *Br J Oral Maxillofac Surg* 25:474–480, 1987
 11. Laine J, Kalimo K, Forssell H, Happonen RP: Resolution of oral lichenoid lesions after replacement of amalgam fillings in patients allergic to mercury compounds. *Br J Dermatol* 126:10–15, 1992
 12. Stejskal VDM, Cederbrant K, Lindvall A, Forsbeck M: MELISA—An *in vitro* tool for the study of metal allergy. *Toxicol In Vitro* 8:991–1000, 1994
 13. Piriilä V: Chamber testing versus patch test for epicutaneous testing. *Contact Derm* 1:48–52, 1975
 14. Hutchinson F, Raffle EJ, Macleod TM: The specificity of lymphocyte transformation *in vitro* by nickel salts in nickel sensitive subjects. *J Invest Dermatol* 58:362–365, 1972
 15. Kreiss K, Newman LS, Mroz MM, Campbell PA: Screening blood test identifies subclinical beryllium disease. *J Occup Med* 31:603–608, 1989
 16. Denman EJ, Denman AM: The lymphocyte transformation test and gold hypersensitivity. *Ann Rheum Dis* 27:582–589, 1968
 17. Kubicka-Muranyi M, Behmer O, Uhrberg M, Klonowski H, Bister J, Gleichmann E: Murine systemic autoimmune disease induced by mercuric chloride (HgCl₂): Hg-specific helper T-cells react to antigen stored in macrophages. *Int J Immunopharm* 15:151–161, 1993
 18. Walker DM: The inflammatory infiltrate in lichen planus lesions. An autoradiographic and ultrastructural study. *J Oral Pathol* 5:277–286, 1976
 19. Regezi JA, Deegan MJ, Hayward JR: Lichen planus: Immunologic and morphologic identification of the submucosal infiltrate. *Oral Surg* 46:44–52, 1978
 20. Bircher AJ, von Schulthess A, Henning G: Oral lichenoid lesions and mercury sensitivity. *Contact Derm* 29:275–276, 1993
 21. Finne K, Göransson K, Winckler L: OLP and contact allergy to mercury. *Int J Oral Surg* 11:236–239, 1982
 22. Lundström IMC: Allergy and corrosion of dental materials in patients with OLP. *Int J Oral Surg* 13:16–24, 1984
 23. Tigelaar RE, Bergstresser PR, Lonsberry LM, Elmets C, Wood PJ, Streilein JW: Oral ingestion of epicutaneously applied haptens in mice may unwittingly induce down-regulation of contact hypersensitivity. *J Immunol* 129:1898–1904, 1982
 24. Vreeburg KJ, de Groot K, von Blomberg M, Scheper RJ: Induction of immunological tolerance by oral administration of nickel and chromium. *J Dent Res* 63:124–128, 1984
 25. Bolewska J, Holmstrup P, Möller-Madsen B, Kenrad B, Danscher G: Amalgam associated mercury accumulations in normal oral mucosa, oral mucosal lesions of lichen planus and contact lesions associated with amalgam. *J Oral Pathol Med* 19:39–42, 1990
 26. Williams DF: *Biocompatibility of Implant Materials*. London, Pitmans Medical, 1976
 27. Williams DF: *Fundamental Aspects of Biocompatibility II: CRC Series in Biocompatibility*. Boca Raton, FL, CRC Press, 1981
 28. Buchner A, Hansen LS: Amalgam pigmentation (amalgam tattoo) of the oral mucosa. A clinicopathologic study of 268 cases. *Oral Surg* 49:139–147, 1980
 29. Nakayama H, Niki F, Shono M, Hada S: Mercury exanthem. *Contact Derm* 9:411–417, 1983
 30. Young E: Ammoniated mercury poisoning. *Br J Dermatol* 72:449–455, 1960
 31. Mathews KP, Pan PM: Immediate type hypersensitivity to phenylmercuric compounds. *Am J Med* 44:310–318, 1968
 32. Block RM, Sheats JB, Denby Lewis R, Fawley J: Cell-mediated immune response to dog pulp tissue altered by N2 paste within the root canal. *Oral Surg* 45:131–142, 1978
 33. Höök O, Lundgren K-D, Swensson Å: On alkyl mercury poisoning. *Acta Med Scand CL(II)*:131–137, 1954
 34. Jalili MA, Abbasi AH: Poisoning by ethyl mercury toluene sulphonamide. *Br J Ind Med* 18:303–308, 1961
 35. Möller H: Merthiolate allergy: A nationwide iatrogenic sensitization. *Acta Dermatol* 57:509–517, 1977
 36. Pirker C, Möslinger T, Wantke F, Götz M, Jarisch R: Ethylmercuric chloride: The responsible agent in Thimerosal hypersensitivity. *Contact Derm* 29:152–154, 1993
 37. Ellis FA, Robinson HM: Cutaneous sensitivity to merthiolate and other mercurial compounds. *Arch Dermatol Syph* 46:425–430, 1942
 38. von Mayenburg J, Rakoski J, Szliska C: Patch testing with amalgam at various concentrations. *Contact Derm* 24:266–269, 1991
 39. Schöpf E, Schulz KH, Gromm M: Transformation und Mitosen von Lymphocyten *in vitro* durch Quecksilber(II)-chlorid. *Naturwissenschaften* 54:568, 1967
 40. Caron GA, Poutala S, Provost TT: Lymphocyte transformation induced by inorganic and organic mercury. *Int Arch Allergy* 37:76–87, 1970
 41. Nordlind K, Liden S: *In vitro* lymphocyte reactivity to heavy metal salts in the diagnosis of oral mucosal hypersensitivity to amalgam fillings. *Br J Dermatol* 128:38–41, 1993
 42. FDA, National Centre for Devices and Radiological Health, Device Monitoring Branch: Device Experience Network Monthly Report 8:11–12, 1983
 43. Wylie DE, LU D, Carlson LD: Monoclonal antibodies specific for mercuric ions. *Proc Natl Acad Sci USA* 89:4104–4108, 1992
 44. Dayan AD, Hertz RF, Heseltine E, Kazantzis G, Smith EM, Van der Venne MT: Immunotoxicology of metals and immunotoxicology. Proceedings of an International Workshop, IPCS Joint Symposia No. 15. New York, London, Plenum Press, 1990
 45. Goldman M, Druet P, Gleichmann E: TH2 cells in systemic autoimmunity: insights from allogeneic diseases and chemically-induced autoimmunity. *Immunol Today* 12:223–226, 1991

46. Jontell M, Ståhlblad PÅ, Rosdahl I, Lindblom B: HLA-DR3 antigens in erosive oral lichen planus, cutaneous lichen planus, and lichenoid reactions. *Acta Odontol Scand* 45:309-312, 1987
47. Van Der Horst JC, Cirkel PKS, Nieboer C: Mixed lichen planus-lupus erythematosus disease: a distinct entity? *Clinical, histopathological and immunopathological studies in six patients. Clin Exp Dermatol* 8:631-640, 1983
48. Brennum J, Hjelt K: Mb Crohn diagnostiseret ved oral biopsi fra afte. *Nord Med* 101:131, 1986
49. Wyatt EH: Lichen planus and ulcerative colitis. *Br J Dermatol* 93:465-468, 1975
50. Jolly M: Lichen planus and its association with diabetes mellitus. *Med J Aust* 1:990-992, 1972
51. Schralhammer-Benkler K, Ring J, Meurer PM, Landthaler M: Acute mercury intoxication with lichenoid drug eruption followed by mercury contact allergy and development of antinuclear antibodies. *Acta Derm Venereol* 72:294-296, 1992
52. Tibbling L, Thuomas KÅ, Lenkei R, Stejskal VDM: Immunological and brain MRI changes in patients with suspected metal intoxication. *Int J Occupat Med Toxicol* 4:1-10, 1995
53. Danscher G, Horsted-Bindslew P, Rungby J: Traces of mercury in organs from primates with amalgam fillings. *Exp Mol Pathol* 52:291-299, 1990
54. Arvidson B, Arvidsson J, Johansson K: Mercury deposits in neurons of the trigeminal ganglia after insertion of dental amalgam in rats. *BioMetals* 7:261-263, 1994